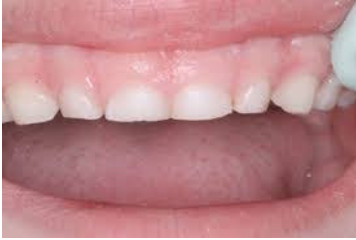

VISUAL KEYS TO PEDIATRIC SLEEP/BREATHING DISORDERS



EVIDENCE OF BRUXING

Evidence of bruxing in children & teens is almost always related to TMJ damage, neck problems, or airway problems.

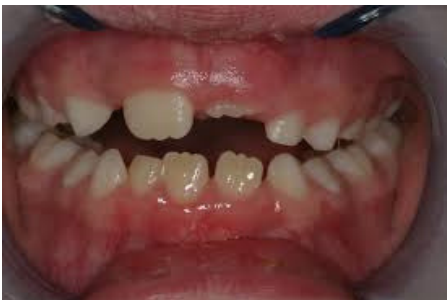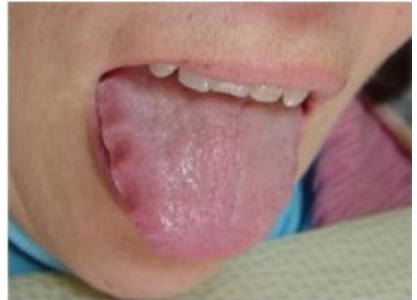It isn't a "stress" issue. TMJ and breathing issues alter the maxillary/mandibular growth.

This leads to compensatory TMJ and breathing issues alter the maxillary/mandibular growth. Which leads to compensatory function and eventual TMJ compression years later.

SCALLOPED TONGUE

Scalloping indicates the arches growth has been severely deflected from the genetic set point of growth; think airway (tonsils/adenoids), lingual frenum.

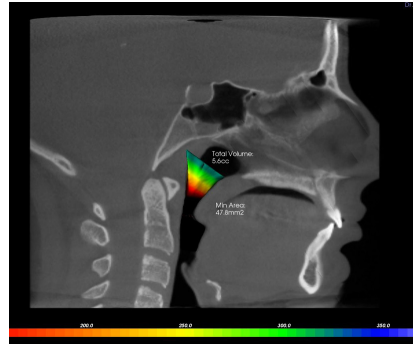
The arches cant hold the tongue without significant encroachment on the posterior airway.



The tongue had to protect the airway from retarded growth of the maxilla. Closing this without imaging for obstruction or getting data can lead to onset of bruxing and TMJ destruction.

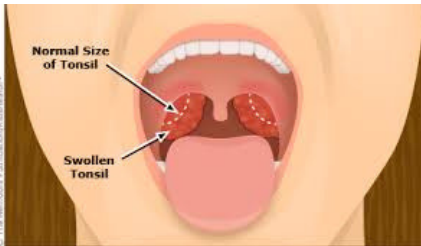
Typical Early Teenage TMJ Patient's Airway Image

Black is HI risk of an obstructed airway. Severe bruxing destroyed the TMJ's which led her to us. Sleep evaluation with evidence to convince the MD's allowed us to get the "causative" problem managed and then deal with the effects (TMJ dislocation and damage).

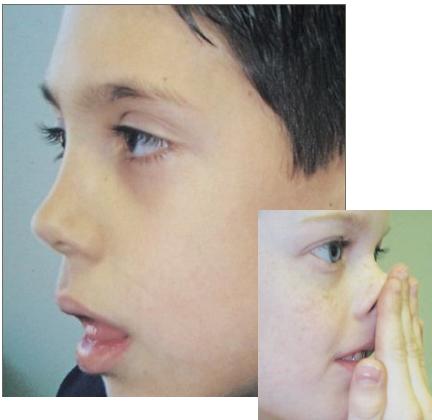
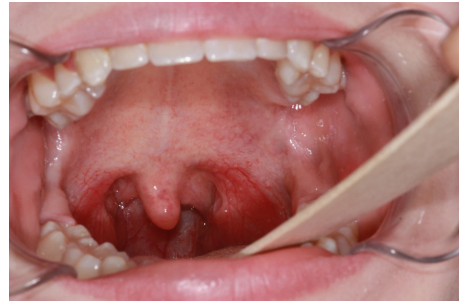
TONSILS

You shouldn't "see" tonsils outside of the crypts. These are grade+ and imaging would likely show a severe airway narrowing. The tonsils will be larger typically down behind the tongue (lingual tonsils).



These tonsils are large and should be removed. MD's can't/won't without strong evidence from the Dentist in terms of documented growth disturbance, behavioral issues (ADD/ADHD-like behavior, significant tiredness, snoring, etc). 3D imaging and a pulse ox study (which we do) are solid evidence they can't ignore.

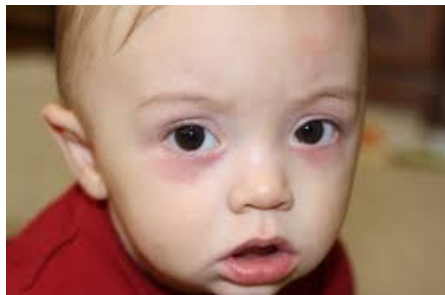

ALLERGIC APPEARANCE

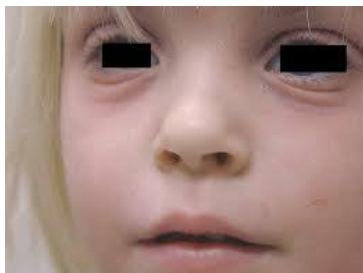Upturned nose from allergic itching, open mouth with an everted lower lip, deep mentalis crease and allergic shiners.

ALLERGIC SHINERS

Adenoid/tonsil enlargement cause stagnation of blood flow in the pterygoid plexus, which retards growth due to physical obstruction and the lowered pH of the region alters maxillary development.



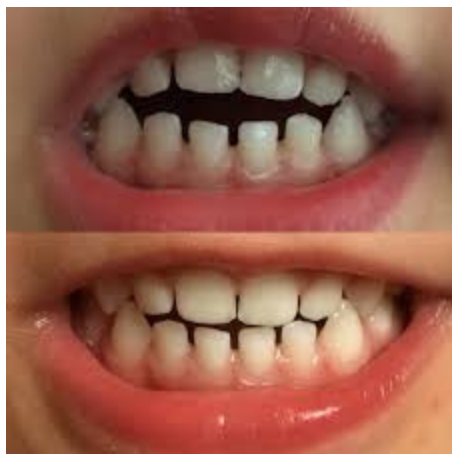Notice everted lip, deep mentalis crease and mouth breathing of this poor infant.



OPEN BITE

Never close an open bite until a thorough airway assessment, sleep assessment and TMJ evaluation are done.

Anterior open bite from tongue thrusting: Myofunctional therapy can close the bite but it worsens the airway obstruction. So many go on to develop TMJ damage, severe bruxing, and other compensatory habits to breathe.



Clear the airway 1st, expand the arches as the Myofunctional experts re-train the tongue (sometimes release the frenum) and growth can really accelerate to try and “fix” things.

